

Internal Medicine  
Section

A Case of Variceal Bleeding with  
Cricopharyngeal Web: A Challenge  
to Variceal Band Ligation

DANDI KRANTHI<sup>1</sup>, DEBABRATA BANERJEE<sup>2</sup>, AMOL S DAHALE<sup>3</sup>, ABHIJEET KARAD<sup>4</sup>, YOGESH BADE<sup>5</sup>



ABSTRACT

Acute Variceal Bleeding (AVB) is a life-threatening complication of portal hypertension that necessitates prompt and effective intervention. Endoscopic Variceal Ligation (EVL) is the primary treatment modality; however, anatomical variations, such as oesophageal webs, can impede the procedure. The present report describes a 40-year-old female patient presenting with haematemesis and melena. Endoscopy confirmed active variceal bleeding, but the advancement of an endoscope equipped with a band ligator was obstructed by a cricopharyngeal web, rendering EVL unfeasible. Haemostasis was initially achieved using sclerotherapy with sodium tetradecyl sulfate. Subsequent endoscopic dilation of the web with a Controlled Radial Expansion (CRE) balloon facilitated successful band ligation. The present case underscores the importance of early recognition of anatomical anomalies and highlights the need for adaptable strategies in the management of AVB, particularly in emergent settings where time is critical. The clinical implications are significant, as the case highlights a previously unreported barrier to EVL in the form of a cricopharyngeal web. It emphasises the necessity for endoscopists to consider anatomical variations when standard procedures fail. The present report contributes to the literature by documenting an unusual clinical scenario that required modification of the standard therapeutic approach to achieve haemostasis in a life-threatening situation.

**Keywords:** Endoscopic variceal ligation, Endoscopy, Oesophageal varices, Sclerotherapy

CASE REPORT

A 40-year-old female with no previous co-morbidities presented with a one-day history of haematemesis and melena. There was no associated epigastric pain, retching prior to the onset of bleeding, or history of Non Steroidal Anti-inflammatory Drugs (NSAIDs) ingestion. There was no history of jaundice, ascites, or hepatic encephalopathy in the past. No family history of chronic liver disease or liver cancer was reported.

On clinical examination, the patient was tachycardic, with a pulse rate of 110 beats per minute, and hypotensive, with a blood pressure of 80/50 mmHg. Her oxygen saturation was 98% on three litres of oxygen via nasal prongs. There was pallor without any icterus, pedal oedema, or peripheral signs of chronic liver cell failure. Systemic examination revealed a palpable spleen 3 cm below the left costal margin. Initial management included haemodynamic stabilisation with fluid resuscitation using 0.9% normal saline and the transfusion of one unit of packed red blood cells. She was administered a 2 mg bolus of terlipressin, followed by a continuous infusion of 3 mg over 24 hours. Additionally, she was treated with intravenous pantoprazole (80 mg stat, followed by 40 mg twice daily) and ceftriaxone (1 g every 12 hours).

Laboratory investigations revealed anaemia and thrombocytopenia [Table/Fig-1]. Abdominal ultrasonography showed moderate splenomegaly with portosystemic collaterals and no evidence of liver surface nodularity, portal vein thrombosis, or portal cavernoma. These findings suggested portal hypertension.

Following informed consent, an upper gastrointestinal endoscopy was performed using a Fujinon EG-760R gastroscope (Fujifilm, Japan) with an outer diameter of 9.4 mm. Resistance was encountered while passing the Upper Oesophageal Sphincter (UES) [Table/Fig-2]; however, the scope was advanced with a slight application of force. Two columns of large oesophageal varices were seen, with active bleeding noted from one of the varices [Table/Fig-2].

It was decided to perform EVL using a Saeed six-shooter multiband ligator (Cook) with an outer diameter of 11.5 mm; however, the

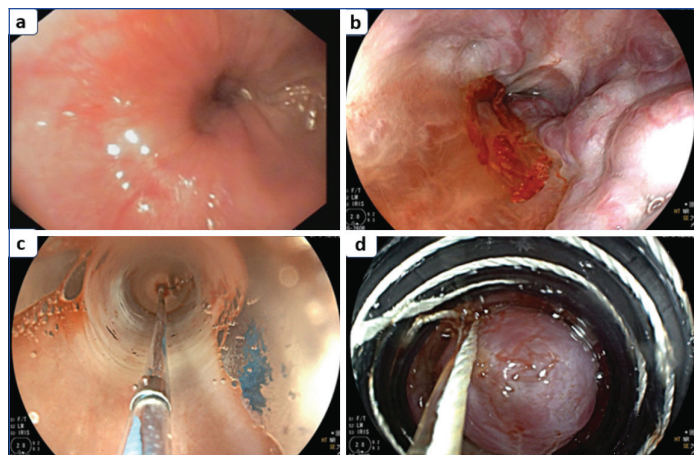
Investigations	Observed value	Reference value
Haemoglobin	7.4 g/dL	12-15 g/dL
TLC	8700/ $\mu$ L	4000-11000/ $\mu$ L
Platelet count	134,000/ $\mu$ L	150,000-450,000/ $\mu$ L
Total bilirubin	0.4 mg/dL	0.3-1.2 mg/dL
Conjugated bilirubin	0.31 mg/dL	0.1-0.3 mg/dL
SGOT	31 U/L	0-40 U/L
SGPT	16 U/L	0-40 U/L
Total protein	7.4 g/dL	6.0-8.0 g/dL
Serum albumin	3.4 g/dL	3.5-5.0 g/dL
Serum globulin	3.0 g/dL	2.0-3.5 g/dL
Sodium	138 mmol/L	135-145 mmol/L
Potassium	4.5 mmol/L	3.5-5.0 mmol/L
PT	15.0 sec	11-14 sec
INR	1.23	0.8-1.2
HIV/HBsAg/anti-HCV	Non reactive	Non reactive

**[Table/Fig-1]:** Laboratory investigations.  
TLC: Total leucocyte count; SGOT: Serum glutamic oxaloacetic transaminase; SGPT: Serum glutamate pyruvate transaminase; PT: Prothrombin time; INR: International normalised ratio; HBsAg: Hepatitis B surface antigen; HCV: Hepatitis C virus; HIV: Human immunodeficiency virus

ligator-equipped endoscope could not be advanced past the UES due to anatomical obstruction. In view of the persistent bleeding and the inability to advance the ligator beyond the UES, sclerotherapy was employed as an alternative therapeutic strategy. A 21G sclerotherapy needle (MEDORAH®) was used to inject 1 mL of 3% sodium tetradecyl sulfate, diluted with normal saline (0.9% NaCl) in a ratio of 1:3, into the bleeding varix, achieving haemostasis. Resistance at the cricopharyngeal region suggested the presence of a partial oesophageal web, which was subsequently dilated endoscopically using a CRE balloon (Boston Scientific) to a diameter of 12 mm [Table/Fig-2].

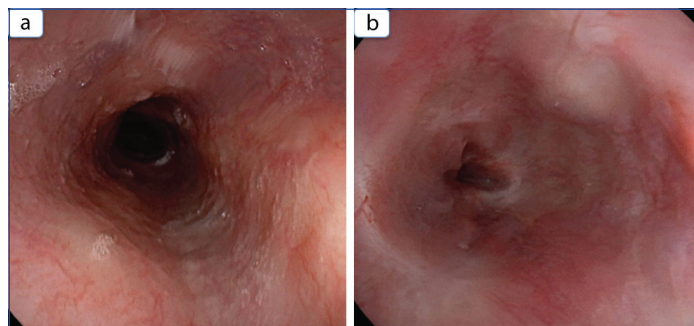
Following successful dilation, the endoscope equipped with the band ligator was passed without difficulty, and two bands were

placed, effectively occluding the varices [Table/Fig-2a-d]. Post-EVL, the patient demonstrated significant clinical improvement, with no further episodes of haematemesis or melena during her hospital stay. There was no hepatic decompensation in the form of ascites or hepatic encephalopathy. The patient was discharged on a non selective beta-blocker (tablet carvedilol 3.125 mg twice daily) for secondary prophylaxis after 48 hours.

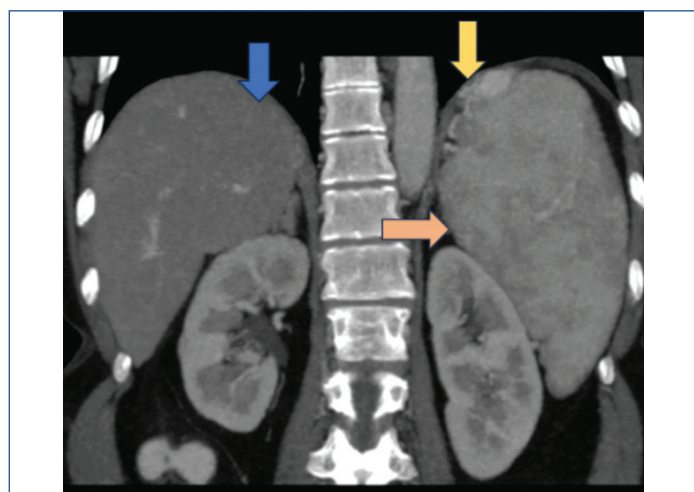


**[Table/Fig-2]:** a) Cricopharyngeal web; b) Oesophageal varices with active bleeding; c) Cricopharyngeal web dilatation with Controlled Radial Expansion (CRE) balloon; d) Oesophageal variceal band ligation.

A follow-up upper GI endoscopy performed three weeks later confirmed the eradication of the varices [Table/Fig-3a,b]. During the same session, a Contrast-enhanced Computed Tomography (CECT) of the abdomen was performed to investigate the underlying etiology of portal hypertension. The imaging revealed a normal liver surface, splenomegaly with a spleen measuring 17 cm, and perisplenic and perigastric collaterals [Table/Fig-4]. Following the CECT abdomen, a percutaneous liver biopsy was performed to substantiate the diagnosis of Non Cirrhotic Portal Fibrosis (NCPF).



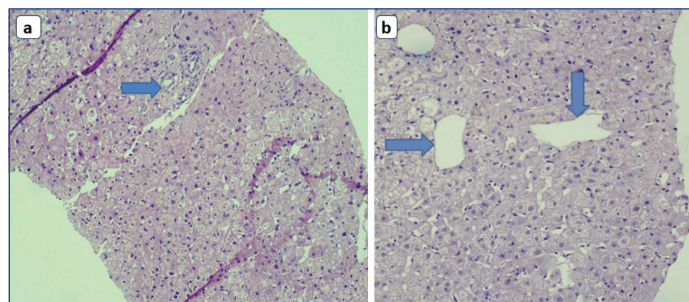
**[Table/Fig-3]:** a,b) Illustrate follow-up endoscopic findings demonstrating the eradication of oesophageal varices.



**[Table/Fig-4]:** CECT abdomen coronal section- The blue arrow highlights a smooth liver surface without nodularity. The orange arrow indicates splenomegaly, while the yellow arrow shows perisplenic collaterals.

Histopathological examination revealed a sclerotic portal tract with the absence of a portal vein, establishing NCPF as the underlying cause of portal hypertension.

The patient remained clinically stable during regular follow-up, with no recurrence of variceal bleeding, and continued on non selective beta-blockers (tablet carvedilol 3.125 mg twice daily orally). The importance of long-term follow-up was emphasised to monitor for and manage potential complications of portal hypertension [Table/Fig-5a,b].



**[Table/Fig-5]:** Histopathological examination of liver biopsy: a) Arrow indicates a sclerotic portal tract with the absence of the portal vein (4x, H&E stain); b) Arrows indicate prominent sinusoidal dilatation (10x, H&E stain).

## DISCUSSION

Acute Variceal Bleeding (AVB) is a severe and life-threatening complication of portal hypertension, with a rebleeding risk of up to 35% within six weeks and a mortality rate ranging from 17% to 20% during this period [1]. Management primarily involves patient stabilisation through fluid resuscitation, blood transfusions, and the administration of vasoactive agents such as terlipressin and octreotide [2-4]. Definitive treatment typically consists of endoscopic techniques, with EVL being the standard care for actively bleeding varices [2-4]. However, anatomical anomalies, such as oesophageal webs, can complicate endoscopic procedures by obstructing the passage of instruments, making EVL more challenging.

Oesophageal webs are thin membranous structures typically located in the cervical or mid-esophagus. Unlike oesophageal rings, which completely encircle the oesophageal lumen, these webs extend only from the anterior oesophageal wall [5]. Although often asymptomatic, they can cause intermittent dysphagia, especially with solid foods. Oesophageal webs are identified in 5-15% of patients undergoing barium swallow studies for dysphagia [6].

Oesophageal webs are commonly associated with conditions such as Plummer-Vinson syndrome, Gastroesophageal Reflux Disease (GERD), eosinophilic oesophagitis, or coeliac disease, all of which can lead to intermittent dysphagia [7]. Occasionally, patients present acutely with food impaction or dysphagia. Imaging studies, such as a barium swallow, are useful in detecting these obstructions, and webs generally respond well to dilation with bougie or balloon dilators [5,6]. The role of a cricopharyngeal web in hindering the passage of endoscopic instruments during the management of AVB has never been reported in the literature, emphasising the unique significance of the present case.

In the present case, a cricopharyngeal web obstructed the advancement of the endoscope, complicating the EVL procedure. Immediate recognition of the web led to a shift in treatment, with sclerotherapy used to achieve haemostasis [8], followed by successful endoscopic dilation of the web. After dilation, EVL was performed without further complications. Sclerotherapy with sodium tetradecyl sulfate, though less commonly used since the advent of EVL, proved effective in controlling the haemorrhage until the web could be dilated.

Esophagogastroduodenoscopy (EGD) remains the gold standard for diagnosing oesophageal varices, as it provides direct visualisation and facilitates targeted therapeutic interventions [9]. The adaptability demonstrated in this case, by using sclerotherapy and dilation before

performing EVL, highlights the need for flexible strategies when anatomical obstacles complicate variceal bleeding management.

Although the association between oesophageal webs and varices in non cirrhotic patients is unclear, the present case underscores the importance of considering such anomalies during emergency procedures. The present case emphasises the importance of early recognition of oesophageal anomalies during emergency endoscopic procedures and demonstrates that alternative therapeutic options, such as sclerotherapy and dilation, can be effective when traditional methods are not feasible. Though rare, cricopharyngeal webs can obstruct endoscopic procedures, and clinicians should be prepared to modify their approach in such situations to ensure successful management of AVB.

## CONCLUSION(S)

The present case demonstrates the challenges posed by oesophageal webs in the management of AVB, highlighting the importance of recognising and addressing anatomical anomalies during endoscopic procedures. Clinicians should be aware of the potential for webs to complicate EVL and be prepared to employ alternative strategies such as sclerotherapy and endoscopic dilation to ensure successful treatment outcomes.

## REFERENCES

- [1] Garcia-Tsao G, Sanyal AJ, Grace ND, Carey W. Prevention and management of gastroesophageal varices and variceal hemorrhage in cirrhosis. *Hepatology*. 2007;46(3):922-38. Doi:10.1002/hep.21907.
- [2] Kaplan DE, Ripoll C, Thiele M, Fortune BE, Simonetto DA, Garcia-Tsao G, et al. AASLD Practice Guidance on risk stratification and management of portal hypertension and varices in cirrhosis. *Hepatology*. 2024;79(5):1180-211. Doi:10.1097/HEP.0000000000000647.
- [3] de Franchis R, Bosch J, Garcia-Tsao G, Reiberger T, Ripoll C, et al. Baveno VII - Renewing consensus in portal hypertension. *J Hepatol*. 2022;76(4):959-74. Doi: 10.1016/j.jhep.2021.12.022.
- [4] Edelson J, Basso JE, Rockey DC. Updated strategies in the management of acute variceal hemorrhage. *Curr Opin Gastroenterol*. 2021;37(3):167-72. Doi: 10.1097/MOG.0000000000000723.
- [5] Feldman M, Friedman LS, Brandt LJ, editors. *Sleisenger and Fordtran's gastrointestinal and liver disease: Pathophysiology, diagnosis, management*. 11th ed. Philadelphia (PA): Elsevier; 2021. Chapter 43.
- [6] Smith MS. Diagnosis and management of oesophageal rings and webs. *Gastroenterol Hepatol (NY)*. 2010;6(11):701-04.
- [7] Petrea OC, Stanciu C, Muzica CM, Sfarti CV, Cojocariu C, Girsleanu I, et al. Idiopathic cervical oesophageal webs: A case report and literature review. *Int J Gen Med*. 2020;13:1123-27. Doi: 10.2147/IJGM.S278999.
- [8] Hartigan PM, Gebhard RL, Gregory PB. Sclerotherapy for actively bleeding oesophageal varices in male alcoholics with cirrhosis. *Gastrointest Endosc*. 1997;46(1):01-07. Doi: 10.1016/S0016-5107(97)70201-3.
- [9] Primignani M. Diagnosis of oesophageal varices. In: de Franchis R, editor. *Variceal hemorrhage*. New York: Springer; 2014. p. 29-43. Doi: 10.1007/978-1-4939-0002-2\_3.

### PARTICULARS OF CONTRIBUTORS:

1. Department of Medical Gastroenterology, Dr. D. Y. Patil Vidyapeeth (Deemed to be University), Pune, Maharashtra, India.
2. Department of Medical Gastroenterology, Dr. D. Y. Patil Vidyapeeth (Deemed to be University), Pune, Maharashtra, India.
3. Department of Medical Gastroenterology, Dr. D. Y. Patil Vidyapeeth (Deemed to be University), Pune, Maharashtra, India.
4. Department of Medical Gastroenterology, Dr. D. Y. Patil Vidyapeeth (Deemed to be University), Pune, Maharashtra, India.
5. Department of Medical Gastroenterology, Dr. D. Y. Patil Vidyapeeth (Deemed to be University), Pune, Maharashtra, India.

### NAME, ADDRESS, E-MAIL ID OF THE CORRESPONDING AUTHOR:

Dr. Debabrata Banerjee,  
A4-1102, Mahendra Antheia, Sant Tukaram Nagar, Pune-411018, Maharashtra, India.  
E-mail: drdbanerjee@gmail.com

### AUTHOR DECLARATION:

- Financial or Other Competing Interests: None
- Was informed consent obtained from the subjects involved in the study? Yes
- For any images presented appropriate consent has been obtained from the subjects. Yes

### PLAGIARISM CHECKING METHODS: [Jain H et al.]

- Plagiarism X-checker: Oct 23, 2024
- Manual Googling: Dec 05, 2024
- iThenticate Software: Dec 16, 2024 (6%)

### ETYMOLOGY: Author Origin

### EMENDATIONS: 6

Date of Submission: **Oct 22, 2024**  
Date of Peer Review: **Nov 20, 2024**  
Date of Acceptance: **Dec 18, 2024**  
Date of Publishing: **Jan 01, 2025**